

CRITICAL ANALYSIS OF THE SEQUENCE AND EXTENT OF THE RESULT OF THE PATHOLOGICAL FAILURE OF SELF-BRACING OF THE SACROILIAC JOINT

Richard L DonTigny PT
Havre, Montana

Abstract:

When the sacrum is loaded with may actually prevent the practitioner from arriving at an superincumbent weight, the sacroiliac joint functions as a self-compensating force couple. This couple creates and tends to rotate around an axis perpendicular to itself. The location of this axis may vary and depends upon the forces applied to the couple. As ligamentous tension increases in the couple, the sacroiliac joints are drawn tightly together through a mechanism of self-bracing. Self-bracing and its normal release or diminution provides for the storage and release of energy, which enhances the efficiency of normal ambulation and which modifies external forces. Failure of the force couple causes failure of the transverse axis of rotation of the sacroiliac joint and failure of the self-bracing mechanism. Because of the decrease in friction and stability, the innominate bones rotate anteriorly on the sacrum on an acetabular axis with the onset of pain and an alteration in apparent leg difference. The resultant dysfunction may range from slight to severe, from minor ligamentous sprains to major sprains, muscle separations, and rents in the joint capsule. These rents may leak synovial fluid to the fifth lumbar nerve root, the lumbosacral plexus, and other tissues; and the resulting lesion may mimic disc dysfunction or create the impression of a multifactorial etiology. However it is seldom included in assessment of low back pain. A critical analysis of the biomechanics demonstrates the sequence and extent of involvement of adjacent tissues and structures, and it provides some direction for the restoration of normal function.

The most commonly accepted procedures for evaluating and treating low back pain were developed and recommended by the American Academy of Orthopaedic Surgeons at their Symposium in Toronto in 1982. Although these procedures appear to be helpful in ruling out potentially serious conditions, even after an extensive work-up, fewer than 15 % of patients can be given a definitive diagnosis*. The lack of apparent movement of the sacroiliac joints (SIJs), the extremely dense structure of the SIJ ligaments, and the lack of knowledge of the function of the SIJs has led to the assumption that they are immune to injury through minor trauma This assumption has meant that the procedures developed for evaluating low back pain are not interpreted relative to dysfunction of the SIJs (SIJD) and thus may not be appropriate to the actual problem, and may actually prevent the practitioner from arriving at an accurate diagnosis over 85 % of the time

The considerable increase in research into the SIJ the past several years²⁻⁴ has

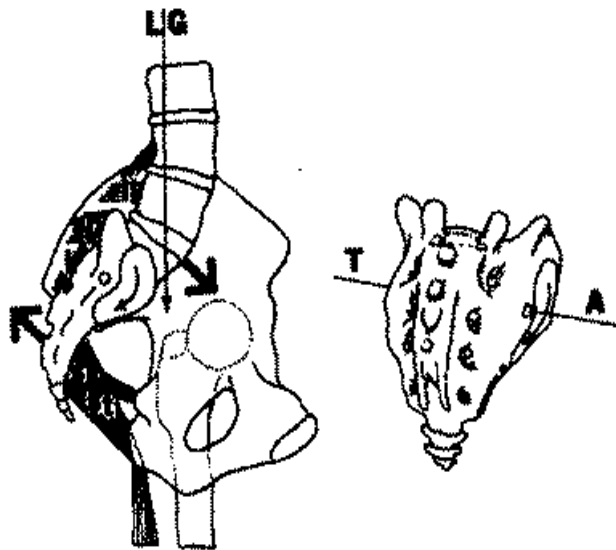
served to illuminate the crepuscular recess in which resides the current art and science of evaluating and managing idiopathic low back pain syndrome. New insight into the functional biomechanics and pathomechanics of these dynamic joints has allowed the development of more relevant testing and more effective treatment of this ubiquitous problem.

This paper reviews the functional biomechanics and pathomechanics of the SIJ end describes the sequence and extent of involvement of various tissues and structures with the increasing severity of the basic pathology. The immediate relief of pain with the restoration of normal function and the simple prevention of SIJD are discussed as well as the implications of invasive procedures.

FUNCTIONAL BIOMECHANICS

Both Cunningham⁵ and Grant⁶ observed that the sacrum narrows towards its dorsal surface, is suspended from the iliac bones by the posterior SIJ ligaments, and as these ligaments tighten the ilia are drawn closer together. The superincumbent weight is transferred from the sacrum through the posterior interosseous ligaments to the ilia and not directly through the SIJs. Vukicevic⁷ found that in the normal standing posture, the posterior interosseous ligaments can sustain a wide range of loading without pelvic or sacral deformation even after the elimination of the sacrotuberous and sacrospinous ligaments, however, these joints become profoundly unstable with the removal of the posterior interosseous ligaments. When moving from supine to an erect posture, vertebral loading on the sacral promontory causes the os to incline ventrally, increasing tensile stress on the posterior interosseous ligaments. The caudal end of the sacrum then moves posteriorly, causing a counter-balancing tensile stress on the sacrotuberous and sacrospinous ligaments. The balanced tensile stress on these ligaments creates a force couple and a tendency to rotate around a transverse axis created by, and perpendicular to, the force couple (Fig. 1). This transverse axis would be force dependent, but may not be anatomically dependents.

Fig. 1: The sacrum and its superincumbent weight, through the line of gravity (LG), is supported by and exerts a tensile stress on the iliolumbar ligaments (il), the short posterior SI ligaments (sp), and the posterior interosseous ligaments (i). A secondary tensile stress is exerted on the



sacrotuberous (St) and sacrospinous (ss) ligaments, creating a force couple (large arrows). The moment of force created by the couple serves as a transverse axis (TA) of rotation. The location of this axis may vary depending upon the direction and degree of the applied force#.

Increased loading of the ventrally inclined sacrum increases tension in the posterior interosseous ligaments and the sacrotuberous and sacrospinous ligaments increasing friction and load transmitting capabilities while protecting the SIJs from shear forces. Vleeming and his associates¹⁰ demonstrated that increased tension on the sacrotuberous ligaments increased tightness in the sacroiliac joint. Grant⁶ referred to this as an automatic locking mechanism and Vleeming and his associates¹⁰ referred to it as a self-bracing mechanism. The balance of forces through the SIJ is assisted by the biceps femoris acting through the sacrotuberous ligament, and (among others) the piriformis and the lower fibers of the gluteus maximus acting to prevent further posterior movement of the sacrum posterior rotation of the innominate bones around a transverse axis through the acetabula would further tense these ligaments and increase friction and pressure on the surfaces of the joint, but would not be expected to cause the innominates to move further posteriorly on the sacrum (Fig. 2 & 3).

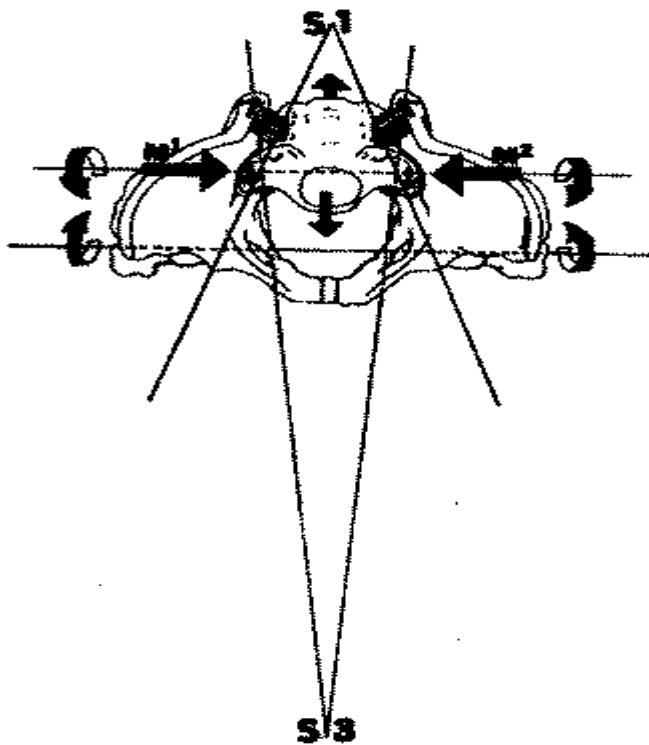


Fig. 2: Top view of the pelvis.

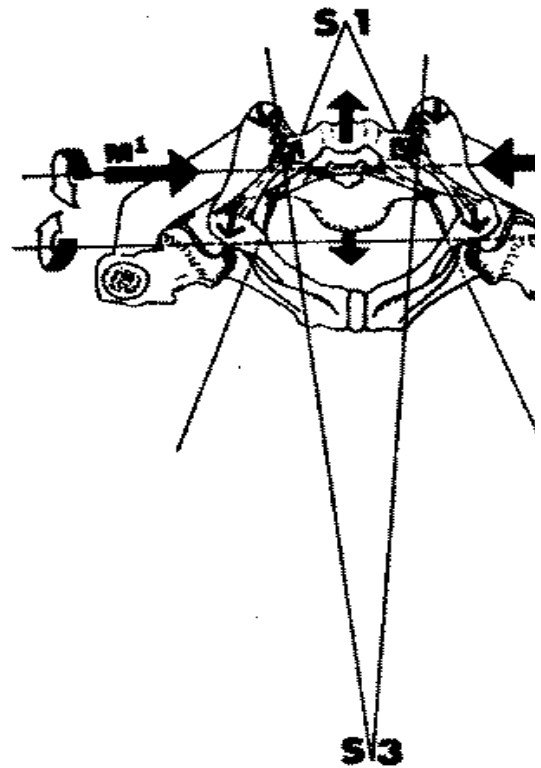


Fig. 3: Bottom view of the pelvis

As the body of the sacrum tends to move anteriorly and downwards with superincumbent tensile stress and is not restricted anatomically by the S1 or the S3 ilial surface, the joint surfaces tend to separate. The joint surfaces only approximate through the action of the moments of force @ (M 1 and M 2) created by the force couples established by the secondary tensile stress on the sacrotuberous ligaments.

Note the direction of tensile stress and with the variation in the angulation of the surfaces of the S1.

During ambulation the SIJ on the side of initial impact self-braces to store energy in the ligaments and fascia while the contralateral SIJ releases stored energy, facilitating the forward movement of the trailing leg and decreasing the energy demands of ambulation. During the brief interval at two-point support, the trunk moves anteriorly and posteriorly with deceleration and recovery¹² occurring simultaneously with rotation and counter-rotation; all of this movement occurs at the SIJs on a force-dependent oblique axis of rotation (Fig. 4). Although researchers have measured movement in the SIJs while subjects moved from supine or neutral standing to the position of two-point support in the asymmetric pelvis, none have measured the movement of the SIJ anteriorly and posteriorly with rotation and counter-rotation on the asymmetric pelvis.

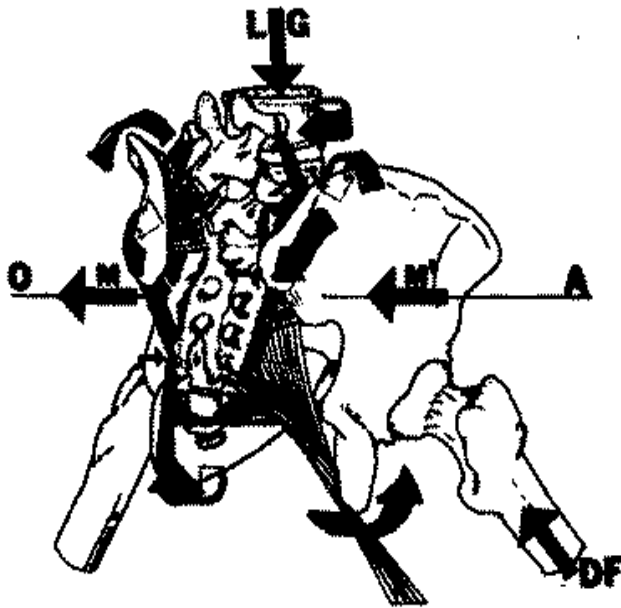


Fig. 4: On the side of initial impact the deceleration force (DF) and the pull of the hamstrings and sacrotuberous ligaments create a force couple with a moment (M') that maintains self-bracing and stabilizes contralateral counter-rotation of the trunk. On the side of flexion, the force couple is reversed creating a moment (M) that decreases self-bracing and releases stored energy. These two different moments result in an oblique axis of sacral rotation.

PATHOMECHANICS

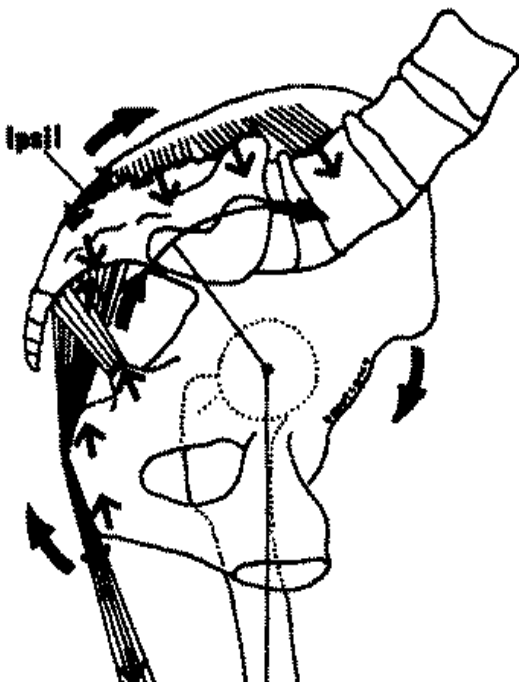


Fig.5: Pathological release of self-bracing with failure of the force couple and resultant movement of the innominate bones on the sacrum on an acetabular axis. This stretches the superficial long posterior SI ligament (Ipsil) and the sacrospinous ligament. An imbalance of tensile forces may cause a shearing stress of the ligamentous and tendinous attachments to the ischial tuberosity.

Low back pain commonly occurs during a transition from an erect posture to a trunk forward posture (or the reverse) while lifting, bending, or lowering. As the superincumbent weight moves anteriorly, the line of gravity moves anterior to the acetabula creating a force in anterior rotation of the innominate bones around the acetabula. At this point, self-bracing can be maintained only by a voluntary contraction of the abdominal muscles to support the anterior pelvis and maintain the

force couple.

Loss of anterior pelvic support allows the innominate bones to rotate anteriorly on the sacrum on an acetabular axis. As the anterior superior iliac spines (ASIS) begin to move downward, the ischial tuberosities move posteriorly and cephalad, decreasing tension on the sacrotuberous ligament, eliminating the force couple and its force-dependent transverse SIJ axis, and decreasing friction at the S3 segment of the sacroiliac joint (Fig. 6). Thus, instead of a normal release of self-bracing on the force-dependent SIJ axis, a pathological release of self-bracing occurs with movement on an acetabular axis, which results in a slight subluxation in anterior rotation of the innominate bones on the sacrum.

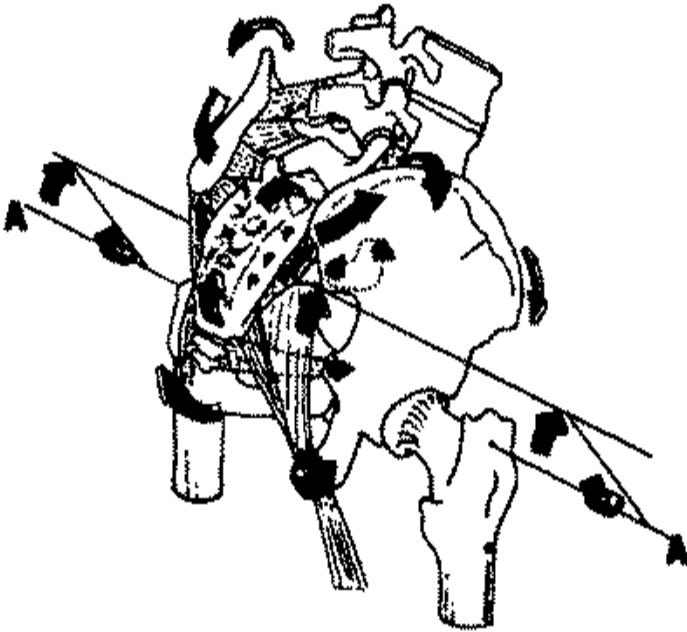


Fig. 6: Oblique view of some of the forces involved with the pathological release of self-bracing on an acetabular axis (AA) and initial application of force at the PSIS. Spinous extension is increased and thus stress on the iliolumbar ligaments may be decreased with a lock of support of the anterior pelvis. Ligamentous tethering by the superficial long posterior SI ligament and by the sacrospinous ligament limits dysfunction.

SEQUENCE OF DYSFUNCTION WITH INCREASED SEVERITY OF SUBLUXATION

The sacrotuberous ligament is helical and its coil tightens to more efficiently store energy with self-bracing. The pathological release from self-bracing can be expected to unwind this helix and may be, in part, responsible for a mechanism of fixator. As tension on this ligament decreases, the innominates tend to move cephalad and laterally on the sacrum with minor subluxation and partial fixation occurring at the S3 segment of the SIJ. Point tenderness is common at the posterior inferior iliac spine (PIIS) but not obvious, as it is frequently obscured by local edema that must be removed through deep massage prior to its identification with deep palpation¹⁶.

A measurable movement of the posterior superior iliac spines (PSIS) cephalad and laterally on the sacrum increases tensile stress on the superficial long posterior sacroiliac ligaments^{11,17}. The lateral movement of the PSISs on the sacrum also stresses the short posterior sacroiliac ligament. Vleeming et al. measured the increase in tensile stress on the superficial long posterior sacroiliac ligament with anterior SIJD. Shuman¹⁹ found tearing of this ligament, and Hackett and Huang²⁰ found hysteresis and decalcification of its attachment to the PSIS with prolonged stretch. Levin²¹ found tightness in the sacrospinous ligament that was then relieved with the correction of the dysfunction. Abnormal stresses on these various ligaments may cause pain over the sacrum and coccyx. Injury to the superficial long posterior sacroiliac ligament may be a major factor in SIJ instability resulting in recurrent SIJD.

With increased severity of dysfunction, the joint capsule may be disrupted. On arthrography of SIJD, Fortin²² reported rents in the anterior capsule at the SI segment and in the posterior capsule at the S3 segment. He further found contrast medium surrounding the L5 nerve root and within the body of the psoas muscle. His arthrographic findings revealed three potential pathways of communication between the SIJ and the neural elements:

- 1) posterior subligamentous extension into the dorsal sacral foramina
- 2) superior recess extravasation at the alar level into the LS epidural sheath, and
- 3) leakage from a ventral tear to the lumbosacral plexus. Fortin suggested that extravasation of inflammatory mediators from a dysfunctional SIJ to adjacent neural tissues may explain the radicular complaints of some patients.

As a tear or injury to the capsule of the knee joint may inhibit function of the quadriceps muscle, it seems possible that a tear of the SIJ capsule may cause a similar muscle inhibition. Dorman and his associates²³ found that when the innominate is held in anterior rotation, the gluteus medius is inhibited. Other muscles may be similarly affected depending upon the level of the joint affected. This should be determined before concluding that the disc is at fault.

Also occurring with this relatively simple dysfunction, the ilial origin of the gluteus maximus may separate from the sacral origin, resulting in a separation of its fibers on a line from that conjoint origin, caudal to the PSIS, to the greater trochanter. This may

precipitate a trochanteric bursitis and pain down the iliotibial tract into the lateral aspect of the knee capsule. This should not be confused with piriformis pain. The piriformis muscle also has a sacral origin and a secondary origin at the superior margin of the greater sciatic notch that may also become strained, but the body of the piriformis is more caudal than the PIIS and deeper. Anteriorly, the ilial origin of the iliacus muscle may be separated from its small secondary origin on the wing of the sacrum. Hip flexor pain may be from this separation, synovial leakage, or both.

As the sacrotuberous ligament is an extension of the tendinous attachment of the biceps femoris to the ischial tuberosity a decrease in ligamentous tension with SIJD may increase shear across that attachment and a tendonitis may result in the biceps femoris. The anterior innominate rotation stresses the biceps femoris and, through that, the ligaments of the head of the fibula, which may become subluxated. This stress may continue distally and cause pain in the peroneus longus. van Wingerden²⁴ found that the peroneus longus may contribute up to 18 % of the stability of the sacrotuberous ligament through the kinetic chain.

With SIJD, the ischial tuberosities tend to move posteriorly toward the coccyx and laterally away from the coccyx. This may distort the muscles and fascia of the pelvic diaphragm. Jungmann²⁵ has pointed out that pelvic congestion plays a major role in the symptomatology noted in female patients with dysmenorrhea, ovarian cysts, and premenstrual syndrome as well as male patients with prostatitis and prostatodynia. Burrows²⁶ associated increased vaginal letorrhea with venous and lymphatic stasis of pelvic congestion. Travell and Simmons²⁷ pointed out that pelvic floor tension and trigger points result in symptoms that may be diagnosed as coccygodynia, levator ani syndrome, proctalgia fugax, or tension myalgia of the pelvic floor and it has been reported that pain from this area often makes sitting uncomfortable. Dyspareunia is a frequent consequence of spasm of the pelvic floor, and pain may also be referred into the groin and testicles, causing a pseudoepidymitis.

Pain in the abdomen at Baer's SI point varies with stress on the SIJ and may be misdiagnosed as appendicitis or ovarian pain. Baer's point has been described as being on a line from the umbilicus to the ASIS 5 cm from the umbilicus²⁸. Norman²⁹ reported relieving this lower abdominal pain by injecting the SIJs.

Although a difference in leg length, frequently treated with heel lifts is thought to be

a cause of back pain, actually it is the mechanism of the dysfunction, the change in relationship between the sacroiliac joint and the acetabula, that always causes changes in apparent leg length. Minor secondary shifts may occur and the leg length on the more painful side may appear to be longer or shorter than the other or, more frequently, the legs may appear to be of equal length, but they will always appear to get shorter with correction of the innominate on the sacrum to the "self-bracing position".

Loss of anterior pelvic support also causes an imbalance in extension and an increase in activity of the sacrospinalis muscle that tends to extend the spine on the sacrum and decrease tensile stress on the iliolumbar ligaments. This causes some instability of the lower lumbar vertebrae. The lumbosacral angle is increased and shear is increased on the lower lumbar discs. The intervertebral foramina are narrowed and the lower discs bulge posteriorly, further encroaching on the foramina. With SLID, as the PSISs move cephalad on the sacrum, tension is decreased further in the iliolumbar ligaments, destabilizing L5-S1 and increasing shear on the discs. Pool-Goudzwaard and associates³⁰ measured this and stated that this explains why the prevalence of herniations at the level of L5-S1 and IA-L5 are higher than other segments in the lumbar spine.

Depending upon the degree and severity of the dysfunction, nearly all of these manifestations may occur some of the time and clinical awareness of these relationships is important. Recognition and diagnosis of SIJD can be made by identifying those manifestations that occur often: the shortening in apparent leg length with corrective mobilization, pain deep in the area of the PIIS near the S3 SIJ segment, pain superficially at the attachment of the superficial long posterior sacroiliac ligament to the PSIS, and slightly less frequently, a painful palpable separation of the fibers of the gluteus maximus as well as pain at the attachment of the short posterior sacroiliac ligament on the medial aspect of the PSIS.

DIAGNOSTIC CONFIRMATION AND TREATMENT

To be valid, a test must be an appropriate, purposeful procedure that demonstrates how and to what degree a lesion or dysfunction varies from normal function. Presently recommended physical tests are not interpreted relative to SIJD and are not helpful in the diagnosis over 85 % of the time. Although initial evaluation must include screening to eliminate potentially dangerous underlying conditions, screening

must include the sacroiliac joint and tests must be interpreted appropriately.

Given the complexities of the functional biomechanics of the SIJs and the considerable number and variety of tissues that can be affected with SIJD, as well as changes in leg length, gait and apparent mimicking of the herniated intervertebral disc, it is difficult to believe that it is all initiated by a subtle, commonly overlooked dysfunction of the innominate bones on the sacrum. If the cause of so much low back pain is so simple, then the relief and management of the problem should also be simple and although simple, it is very precise and appropriate to the problem. As dysfunction of the SIJ essentially occurs with a pathological release from self-bracing in anterior rotation all that is needed to restore function is to return the joint posteriorly to the self-bracing position.

As the innominate bones rotate anteriorly on the sacrum on an acetabular axis, the sacrum rises relative to the acetabula causing the legs to appear to lengthen, sometimes one more than the other. They can be expected to become shorter when the posterior aspect of the innominate bones is rotated downward and the anterior aspect upward on an acetabular axis to restore the self-bracing position. The key is to move the PSISs posteriorly, caudally and medially on the sacrum where the fixation occurs. The resultant shortening of the leg is a measurable, objective, positive, and predictable sign occurring with correction that relieves pain and restores function to the SIJ. This shortening of apparent leg length is accompanied by a measurable movement of the PSISs caudal and medially on the sacrum and can be observed by approximating the medial malleoli in the midline before and after mobilization with the patient in supine.

Probably the simplest and safest method of mobilization to the self-bracing position is to stand to one side of the supine patient, grasp an ankle with both hands, lift the leg to about 40–50 degrees of passive straight leg raising, and put a strong sustained pull on that leg in the long axis for about 5–10 seconds. No jerking popping, or twisting is necessary. Put that leg down and examine the relative leg length at the malleoli. That leg will now appear to be one to three cm shorter than it was previously. Repeat this procedure with the other leg and that leg will also appear to shorten. Repeat this procedure with the first leg again and it will probably appear to shorten even more. Keep repeating this procedure while alternating sides, (R, L, R, L, R, L) until no more apparent shortening occurs. The SIJs are incredibly strong, high friction joints and must be wobbled back into self-bracing a little bit at a time, rather like a

stuck drawer. The legs should appear to be of equal length after correction.

Several other methods may be used to rotate the innominate bones posteriorly on the sacrum (Fig. 7) by using the leg as a lever, grasping the innominate directly and rotating it posteriorly, or with muscle energy techniques. Always examine the comparative leg length at the malleoli before and after each procedure. It is both interesting and enlightening to mobilize or pull on a short or on a long leg and watch it become considerably shorter.

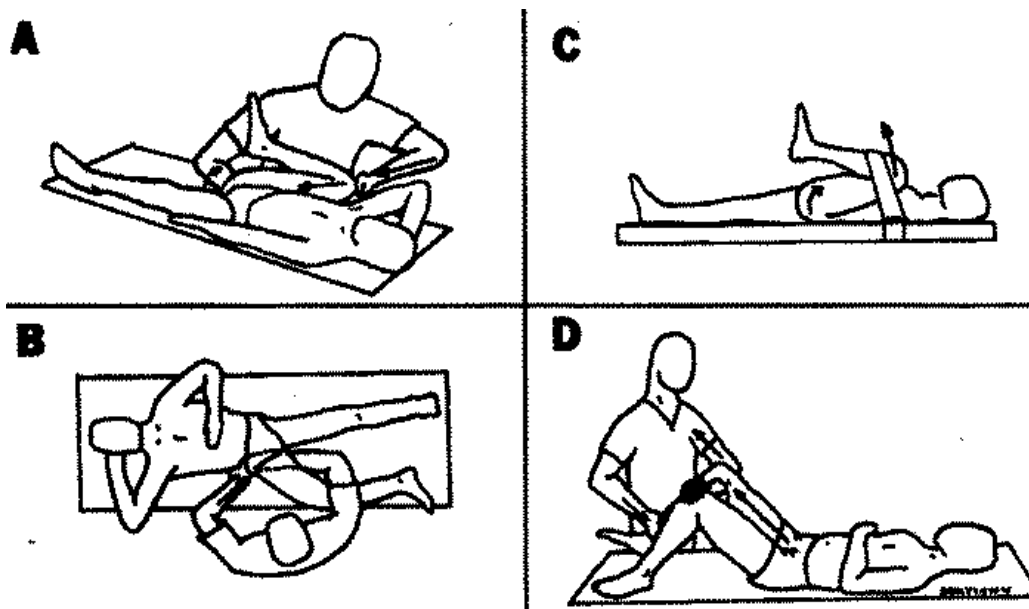


Fig. 7: Various methods of manual correction of dysfunction to restore self-bracing. (A) Using the leg as a lever. (B) Direct mobilization to cause the PSISs to move caudally and medially on the sacrum (C) Isometric hip extension against a strap. (D) Using the contralateral knee as fulcrum while distracting the thigh and pelvis with the forearm. Just enough pressure is put on the lower leg with the other hand to keep the knee from extending. This is a very effective method of correction, simple and painless.

CORRECTIVE EXERCISES

The patient must begin self-correction exercises as soon as possible after onset to correct the dysfunction and to maintain the correction either by using a direct stretch (Fig. 8) or a strong isometric hip extension (Fig. 9). Any of these exercises can be used depending upon convenience, ability, and individual efficacy of response. The selected exercises should be performed alternately on each side at least three times. If the pain is severe, the exercise should be repeated every two hours throughout the day for four to five days, then three to four times daily for a week, then as needed. Self-correcting at bedtime allows the joints to stay unstressed during the hours of

sleep. When the patient is supine or prone, the SIJs are unloaded and somewhat unstable. An elastic garment or support can be worn at night to provide some stability and comfort.

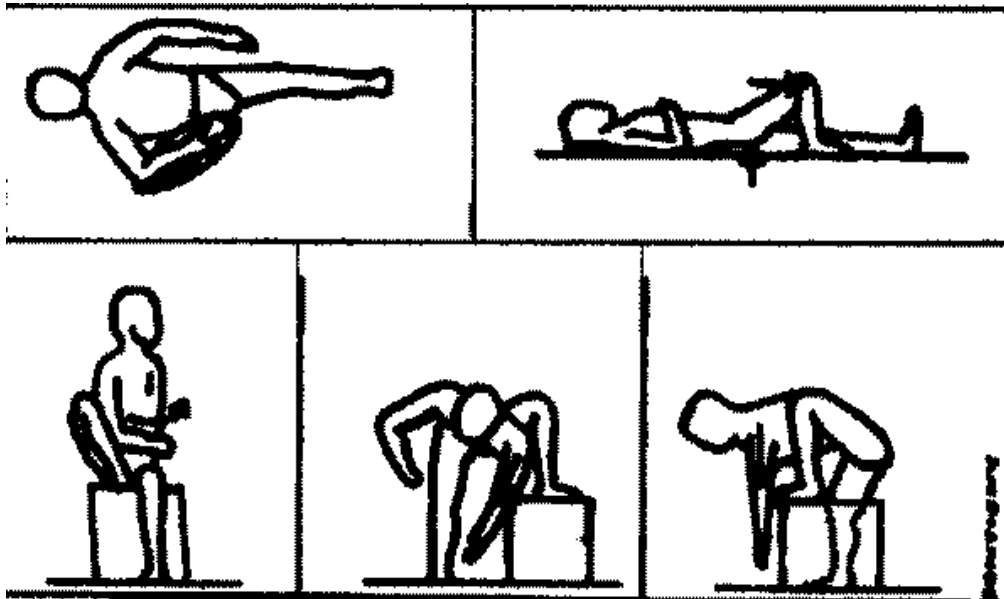


Fig. 8: Restoration of the self-bracing position using a direct stretch can be carried out while sitting, standing or lying.

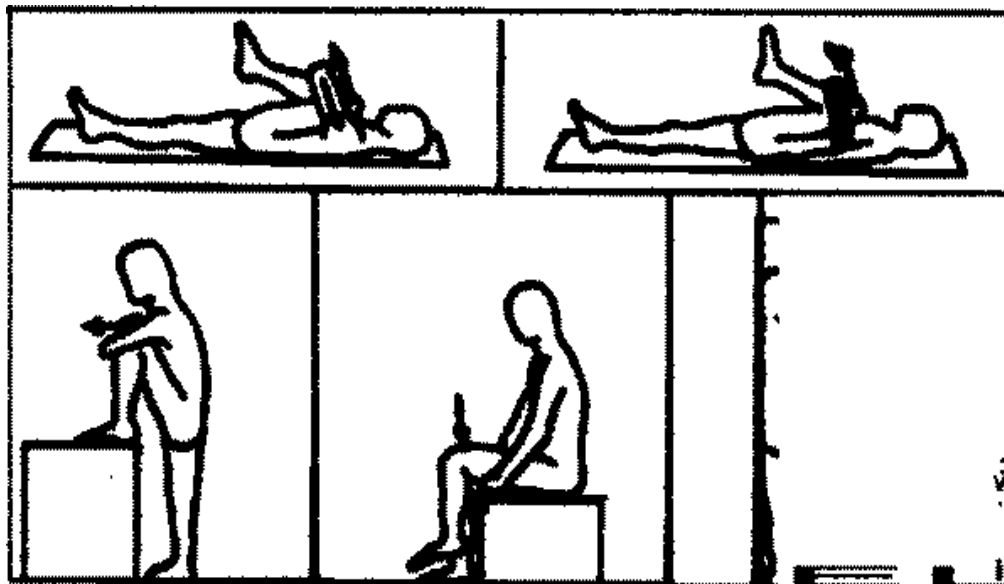


Fig. 9: Muscle energy techniques can be used in a variety of positions.

PREVENTION

Effective prevention of onset or recurrence of SIJD is achieved by actively supporting

the anterior pelvis with the abdominal muscles to maintain the self-bracing mechanism when standing and especially while leaning forward to perform any task. An active contraction of the gluteals will also serve to reinforce self-bracing. Depending upon individual fitness, muscles most involved in maintaining the self-bracing mechanism may have to be strengthened. It is not enough to be strong, you must maintain an active contraction while leaning forward to maintain self-bracing.

To protect the low back while lifting, a flattened pelvis and lumbosacral angle are necessary. This maintains self-bracing, tightens the iliolumbar ligaments, and allows the superincumbent weight to be born by the body of the sacrum, the discs, and the vertebrae. The spine must be straight. To lift while trying to maintain so-called normal curves increases shear forces on the discs.

MODALITIES AND SUPPORTS

Modalities cannot be expected to be helpful in treating low back pain if the self-bracing mechanism remains impaired. However, after manual correction of the SIJs to restore the self-bracing position, modalities can provide a great deal of relief. My personal choice is heat and electrical stimulation for 30 minutes followed by massage to relieve any residual soreness and to decrease swelling and congestion in the gluteals.

A good lumbosacral support can be helpful to stabilize the SIJs but it should be put on when the patient is supine and after a correction has been made. If the support is put on without correcting the dysfunction, it may increase pain by increasing pressure on the uncorrected joints. The support must be worn low around the pelvis with the bottom of the support at the trochanters.

INVASIVE PROCEDURES

Norman and May³¹ treated over 300 patients with injection of local anesthetic into the SIJs, relieving pain immediately in patients who had both sensory changes and an absent Achilles reflex. Therapeutic results were obtained by adding hydrocortisone to the anesthetic. Several patients with continuing low back pain following one or two laminectomies for the removal of discs were successfully treated after three or four injections.

Schwarzer³² found a weak but statistically significant correlation between SI ventral

tears and the relief of pain upon the anesthetization of the joint. Since most of the tissues affected by SIJD are extra-articular, this relief of pain in the presence of ventral tears probably indicates the leakage of the anesthetic into adjacent lesioned structures. If pain is not relieved with injection into an intact SIJ, the clinician cannot rule out the presence of SIJD as this may only indicate the encapsulation of the anesthetic. Local blocks to specific structures especially in the area of the PIISs and the PSISs would probably be more effective and more accurately indicate the presence of SIJD.

A number of physicians have reported excellent results in the stabilization of the unstable SIJs with proliferant injections. Arthrodesis of the unstable SIJs may also provide good relief of chronic low back pain or the unstable backs. It may be possible to preserve normal function in the SIJs by strengthening the superficial long posterior sacroiliac ligament with tissue borrowed from the adjacent sacrospinalis tendon. In my opinion, it is essential to do any of these procedures after correction of SIJD when the SIJs are in the self-bracing position.

FREQUENCY OF OCCURRENCE

An outcome audit of 145 patients with low back pain in 1969 found 80% to have SIJD. Physical therapy treatments averaged 5.9 per patient³⁹. In 1971, a similar audit of 54 consecutive outpatients with low back pain revealed that 83.3% had SIJD. Treatments averaged 2.9 per patient and relief was frequently dramatic³⁹. Shati in 1992 reported the results of a study of 1000 consecutive cases of low back pain and found 98% to have SIJD. His surgical incidence for herniated discs dropped to 0.2%.

With rigorous and exacting application of these described principles and procedures, the practitioner can expect over 90% of all patients with low back pain (acute, chronic, moderate, severe, during pregnancy, or from failed backs) to be essentially free of pain following manual correction of the SIJs to the self-bracing position. The legs will appear to be of equal length and the iliac crests will be level. The pain, of course, may recur without appropriate corrective exercises or procedures to stabilize the unstable SIJ.

SUMMARY

The lumbosacral complex appears to function as a self-compensating force couple with a moment of force that serves as a variable, force-dependent transverse axis,

usually through the posterior aspect of the SIJ. This force couple increases joint stability through a principle of self-bracing, which allows greater ligamentous tension for the storage and release of energy and serves to balance forces of gravity, weight-loading, inertia, rotation, and acceleration and deceleration.

A pathological release of self-bracing may occur if the abdominal muscles fail to support the anterior pelvis when the line of gravity moves anteriorly. The innominate bones then move on the SIJs on an acetabular axis with fixation, which may be extra-articular. The resulting dysfunction may mimic disc dysfunction or may give the impression of a multifactorial etiology that prevents normal function of the force couple. Treatment of SIJD and the restoration of normal function can be accomplished by manually moving the posterior aspect of the innominate bones caudally and medially on the sacrum on an acetabular axis to the self-bracing position. The legs always appear to shorten with this correction, the leg length will be equalized and the pelvis level. Prevention of dysfunction occurs through the maintenance of self-bracing with an active contraction of the abdominal muscles, especially when leaning forward to perform any task.

CONCLUSION

This is the most likely mechanism of idiopathic low back pain syndrome, a subtle, measurable, reversible, biomechanical lesion of the SIJs that is a commonly overlooked variation from normal. It is easily corrected and preventable with proper exercise.

ACKNOWLEDGMENT

I am grateful to Thomas Dorman, MD, for his support and assistance in reviewing this manuscript.

EDITOR'S ACKNOWLEDGMENT

The editor is most grateful to the author and to the board of The Journal of Manual & Manipulative Therapy for the offer to publish this paper concurrently. (JMMT 1999; 7: 173-181)

Address all correspondence and request for reprints to:

Richard DonTigny, PT

66 15th Street West
Havre, MT 59501 USA

REFERENCES

1. White AA, Gordon SL (eds). American Academy of Orthopaedic Surgeons Symposium on Idiopathic Low Back Pain. St. Louis: C.V. Mosby Company, 1982.
2. Vleeming A, Mooney V, Snijders C, and Dorman T (eds). Low Back Pain and its Relation to the Sacroiliac Joint. Rotterdam: Philips, 1993.
3. Vleeming A, Mooney V, Snijders C, and Dorman T (eds). The Function of the Lumbar Spine and Sacroiliac Joint Part I and II. Rotterdam Philips, 1995.
4. Vleeming, Mooney V, Dorman T, Snijders, Stoeckart R (eds). Movement Stability & Low Back Pain: The Essential Role of the Pelvis. London: Churchill Livingstone, 1997.
5. Cunningham DJ, cited by Dwight T, et al: Human Anatomy, Including Structure and Development and Practical Considerations. Edited by GA Piersol Philadelphia, J.B. Lippincott Co., 1907, p 346.
6. Grant JCB: A Method of Anatomy. Descriptive and Deductive, Sixth Edition, Baltimore, Williams & Wilkins Co., 1958.
7. Vukicevic S, Marusic A, Stavljenic A, Vujicic C, Skavic J, Mukicevic D: Holographic analysis of the human pelvis. Spine 16:209-214, 1991.
8. DonTigny RL: Function of the lumbosacroiliac complex as a self-compensating force couple with a variable, force-dependent transverse axis: A theoretical analysis. The Journal of Manual and Manipulative Therapy 2:87-93, 1994.
9. Vleeming A, van Wingerden JP, Snijders CJ, Stoeckart R, Stijnen T: Load application to the sacrotuberous ligament influences on sacroiliac joint mechanics. Clin Biomech. 4:204-209, 1989.
10. Vleeming A, Volkers ACW, Snijders CJ, Stoeckart R: Relation between form and function in the sacroiliac joint Part 2: Biomechanical Aspects. Spine 15:133-136, 1990.
11. DonTigny RL: Mechanics and treatment of the sacroiliac joint. J of Manual & Manipulative Therapy, 1:3-12, 1993.
12. Thorstensson A, Nilsson J, Carlson H, Zomlefer MR: Trunk movement in human locomotion. Acta Physio Stand 121:9-22, 1984.
13. Lavignolle B, Vital JM, Senegas J, et al: An approach to the functional anatomy of the sacroiliac joints in vivo. Anatomia Clinica 5: 169-176, 1983.

14. Stuesson B, Selvik G, Uden A: Movements of the sacroiliac joints. A roentgen stereophotogrammetric analysis. *Spine* 14: 162–165, 1989.
15. Smidt GS, McQuade K, Wei SH, Barakatt E: Sacroiliac kinematics for reciprocal stride positions. *Spine* 20 (9):1047– 1054,1995.
16. DonTigny RL: Mechanics and treatment of the sacroiliac joint. In Vlemming A, Mooney V, Dorman T, Snijders E, Stoeckart R. (eds) *Movement, Stability & Low Back Pain: The Essential Role of the Pelvis* London: Churchill Livingstone, 1997, pp 461–476.
17. DonTigny RL: Measuring PSIS movement. *Clinical Management* 10:43–44,1990.
18. Vleeming A, Pool-Goudzwaard AL, Hammudoghlu D, Stoeckart R, Snijders CJ, Mens JMA: The function of the long dorsal sacroiliac ligament: Its implication for understanding low back pain. In Vleeming A, Mooney V, Dorman T, Snijders CJ (eds) *The Integrated Function of the Lumbar Spine and Sacroiliac Joint*. Rotterdam: Philips, 1995, pp 125–137.
19. Shuman D: Technic for treating instability of the joints by sclerotherapy *Osteopathic Profession*, May 1953.
20. Hackett GS, Huang TC: Prolotherapy for sciatica from weak pelvic ligaments and bone dystrophy. *Clinical Medicine* 8 (12): 2301–2316, 1991.
21. Confirmed by Levin SM, personal communication, 1996.
22. Fortin JD: Sacroiliac joint injection and arthrography with imaging correlation. In: Leonard T (ed.) *Physiatric procedures in clinical practice* Harley & Belfus, Philadelphia, 1995.
23. Dorman TA, Brierly S, Fray J, Pappani K: Muscles and pelvic clutch: hip adductor inhibition in anterior rotation of the ilium. *Journal of Manual and Manipulative Therapy* 3:85–90, 1995.
24. van Wingerden JP: (in preparation) cited in: Vleeming A, Snijders C J, Stoeckart R, Mens JMA: The role of the sacroiliac joints in coupling between sly, pelvic legs and arms. In Vleeming A, Mooney V, Drama T, Snijders C, Stoeckart R (eds): *Movement, Stability & Low Back Pain; The Essential Role of the Pelvis*. London, Churchill Livingstone 1997, p 68.
25. Jungman M: Abdominal–pelvic pain caused by gravitational strain *Southwestern Medicine* 42(11), November 1991.
26. Burrows EA: Disorders of the female reproductive system In Hoad JM: *Osteopathic Medicine*, New York, McGraw–Hill, 1969, Chapter 42, p 681.
27. Travell JG, Simons 13(3): *Myofascial Pain and Dysfunction: A Trigger Point Manual (Vol II)*, Baltimore, Williams & Wilkins, 1992, pp 110–131.

28. Mennell JB: The Science and Art of Joint Manipulation: The Spinal Column. London, J & A Churchill Ltd, 1952, -012, p 90.
29. Norman OF: Sacroiliac disease and its relationship to lower abdominal pain. Am J Surg 116:54-6, Jul 1968.
30. Pool-Goudzwaard AL, Hock van Dijke G, Vleeming A, Snijders CJ, Mere JMA: The iliolumbar ligament influence on the coupling of the sacroiliac joint and the L5-SI Segment. In Vleeming A, Mooney V, Tilscher H, Dorman T, Snijders C (eds): The Third Interdisciplinary World Congress on Low Back & Pelvic Pain. Vienna, Ausaia, November 19-21, 1998 (ISBN 90-802551-2-2) 313-5.
31. Norman GF, May A: Sacroiliac conditions simulating intervertebral disc syndrome. West J Surg Obstet Gynecol 64:46t-2, Aug 1956.
32. Schwarzer AC, Aprill CM, Bogdok N: The sacroiliac joint in chronic low backpain. Spine 20(1):31-7, 1995.
33. Ongley MJ, Klein RG, Dorman TA et al -A new approach to the treatment of chronic back pain. Lancet 2: 143-6, 1987.
34. Dorman T: Treatment for spinal pain arising from the ligaments using prolotherapy a retrospective survey. Journal of Orthopaedic Medicine. 13(1):13-19, 1991.
35. Smith-Petersen M, Rogers W: End-result study of arthrodesis of the sacroiliac joint for arthritis, traumatic and non-traumatic. Journal of Bone and Joint Surgery 8:118-136, 1926.
36. Moore M: Diagnosis and surgical treatment of chronic painful sacroiliac dysfunction. In: Vleeming A, Mooney V, Dorman T, Snijders C (eds) Second Interdisciplinary World Congress on Low Back Pain San Diego, CA, Nov 9-11, 1995, pp 339-354.
37. Keating JG, Avillar MD, Price M: Sacroiliac joint arthrodesis in selected patients with low back pain. In: Vleeming A, Mooney V, Dorman T, Snijders C, Stoeckart R (eds): Movement, Stability & Low Back Pain: The Essential Role of the Pelvis. London, Churchill Livingstone, 1997, pp 573-586.
38. Lippitt AB: Percutaneous fixation of the sacroiliac joint. In: Vleeming A Mooney V, Dorman T, Snijders C, Stoeckart R (eds): Movement, Stability & Low Back Pain: The Essential Role of the Pelvis. London, Churchill Livingstone, 1997, pp 587-594.
39. DonTigny RL: Evaluation, manipulation and management of anterior dysfunction of the sacroiliac joint. DO 14:215-226, 1973.
40. Shaw if: The role of the sacroiliac joint as a cause of low back pain and dysfunction. In: Vleeming A, Mooney V, Snijders C.J, Dorman T (eds): First Interdisciplinary World Congress on Low Back Pain and its Relation to the Sacroiliac Joint. San Diego, CA, 5-6 November 1992, lap 67-80.