

Surgery for osteitis pubis

Ramin Mehin, MD; Robert Meek, MD; Peter O'Brien, MD; Piotr Blachut, MD

Background: Osteitis pubis is a rare and self-limited condition. Surgery may be necessary in 5%–10% of cases. The outcome after surgery for osteitis pubis is not known. **Methods:** To determine the success of surgical intervention for osteitis pubis, we used a computerized data registry to identify patients (10 women [mean age 40 yr]) who underwent surgery for osteitis pubis. A retrospective chart review was carried out. We also searched the literature for all cases of osteitis pubis managed surgically and identified 73 cases. **Results:** The 10 patients in our series had had symptoms for a mean of 4 years preoperatively. Onset of pain was insidious in 4 patients, it followed childbirth in 4 and it followed trauma in 2. Depending on the surgeon's preference, either a wedge resection of the symphysis pubis was performed or a symphysiodesis. At the latest follow-up (average 26 mo), although all patients had some improvement, only 6 of 10 patients were satisfied with the outcome. From the literature review, we identified 3 categories of patients with osteitis pubis: elite athletes, patients with postoperative or infectious osteitis pubis and the remainder, which would include the patients in our series. **Conclusions:** Four types of surgical intervention are described: curettage, arthrodesis, wedge resection and wide resection. The elite athletes respond well to curettage. Patients with osteitis pubis following urologic or gynecologic procedures or have a proven infection require surgery in roughly 50% of cases. The third group has an unpredictable outcome.

Contexte : L'ostéite pubienne est un problème rare et résolutif. La chirurgie peut s'imposer dans 5 à 10 % des cas. On ne connaît pas l'évolution de l'état de santé suite à une intervention chirurgicale pour ostéite pubienne. **Méthodes :** Afin de déterminer le taux de succès de l'intervention chirurgicale pour ostéite pubienne, nous avons utilisé un registre informatisé pour identifier des patientes (10 femmes [âge moyen de 40 ans]) qui ont subi une intervention chirurgicale pour ostéite pubienne. Nous avons procédé à une étude rétrospective des dossiers. Nous avons aussi effectué une recherche documentaire sur tous les cas d'ostéite pubienne traitée par intervention chirurgicale et nous en avons trouvé 73. **Résultats :** Les 10 patientes de notre série avaient des symptômes depuis quatre ans en moyenne avant l'intervention. L'apparition de la douleur a été insidieuse chez quatre patientes, a suivi l'accouchement dans quatre autres cas et un traumatisme dans deux cas. On a procédé à une résection cunéiforme de la symphyse pubienne ou à une symphysiodèse, selon la préférence du chirurgien. Au dernier suivi (26 mois en moyenne), même si toutes les patientes avaient constaté une certaine amélioration, seulement 6 sur 10 étaient satisfaites du résultat. À la suite de la recherche documentaire, nous avons déterminé trois catégories de patientes souffrant d'ostéite pubienne : les athlètes d'élite, les sujets atteints d'ostéite pubienne postopératoire ou infectieuse, et les autres, catégorie qui incluait les patientes de notre série. **Conclusions :** On décrit quatre types d'interventions chirurgicales : curetage, arthrodèse, résection cunéiforme et résection large. Les athlètes d'élite répondent bien au curetage. Les patientes atteintes d'une ostéite pubienne consécutive à une intervention urologique ou gynécologique, ou qui ont une infection démontrée, ont besoin d'une intervention chirurgicale dans à peu près 50 % des cas. Pour le troisième groupe, le résultat est imprévisible.

Osteitis pubis, a rare condition, was initially described in the English literature by Beer¹ and in the French literature by Legueuc.² It may result from infection or sterile inflammation. It is characterized by

sharp or aching anterior pelvic pain centred over the symphysis pubis, in the lower abdominal muscles or in the perineum. The pain may radiate along the adductor region of the thigh, and patients may describe

painful adductor muscle spasms. Aggravating factors are walking and standing from a seated position.

In this paper we deal with noninfectious osteitis pubis. In the majority of such cases the condition usually

From the University of British Columbia, Vancouver General Hospital, Vancouver, BC

Accepted for publication Feb. 8, 2005

Correspondence to: Dr. Ramin Mehin, 960 Prospect Ave., North Vancouver BC V7R 2M4; fax 604 875-4677; rmehin@hotmail.com

resolves spontaneously or the patient responds to medical therapy. Various modes of medical management have been described, including rest, administration of anti-inflammatory medications, oral and injected steroids, antibiotics, and physical therapy with or without anticoagulation.³⁻¹³ However, a small number of patients do not respond to medical therapy and require a surgical procedure.

There is a paucity of information regarding the outcome of surgical intervention. The purpose of this study was to determine the success of surgery for osteitis pubis by reviewing the experience at our centre and comparing this to results in the scientific literature.

Methods

With use of a computerized surgical registry, we identified 10 patients who had undergone a surgical procedure for osteitis pubis. All 10 were women, and their average age was 40 (range 20-55) years. Nine patients complained of pain overlying the pubis; the chief complaint of the remaining patient was a sensation of instability at the symphysis pubis. In

all patients, pain was brought on when standing up from a chair or walking. Local palpation over the symphysis pubis elicited tenderness. Before surgery, all patients but the one whose chief complaint was of instability had undergone a positive diagnostic injection of the symphysis pubis. In addition, 3 patients had had a diagnostic laparoscopy to rule out other causes of the pain.

Patients had been symptomatic for a mean period of 4 years (range 18 mo-10 yr) before the surgical intervention. In 4 women the onset of the pain had followed childbirth; 2 patients had an acute traumatic episode before the onset of pain; and in the other 4 the onset of symptoms was insidious.

The decision to carry out surgery was based on the characteristic symptoms and signs along with the positive diagnostic symphyseal injection.⁶ Furthermore, all patients had exhausted nonoperative therapy before being referred to our centre.

Investigations

Eight patients had plain radiography preoperatively. Seven of the 8 had

typical radiographic findings of a widened, irregular joint line and subchondral sclerosis (Table 1, Fig. 1). Six patients had computed tomography (CT); in 5, subchondral sclerosis was the main finding (Table 1, Fig. 2). Four of 6 patients who underwent bone scanning were found to have increased uptake at the symphysis pubis on delayed views (Table 1). Three of 4 patients who had magnetic resonance imaging (MRI) had no abnormal findings. One MR image demonstrated an irregular joint line, mild soft-tissue reaction anteriorly but no bone marrow edema (Table 1, Fig. 3).

Surgical technique

Patients were positioned supine. A Foley catheter was inserted. Pfannenstiel's incision was used. Scarpa's and Camper's fasciae were incised exposing the abdominal fascia. A vertical incision was made along the linea alba. To protect the bladder, a malleable retractor was placed behind the symphysis in the space of Retzius. Sharp dissection was used to lift off the insertion of the rectus abdominis and expose the symphysis pu-

Table 1
Findings on preoperative imaging studies in 10 women with osteitis pubis

No.	Plain radiography	CT	MRI	Bone scanning
1	—	Normal	Normal	Normal
2	Irregular joint line, sclerosis, cysts	Sclerosis at symphysis, joint space normal	—	Delayed images increased uptake
3	Radiolucency, irregular joint line, sclerosis	—	—	Increased uptake at symphysis
4	Loss of cortical margins, lytic erosions	—	Normal	Increased uptake at symphysis
5	Abnormal joint line, widened joint line and sclerosis	Sclerosis	Normal	Increased uptake at symphysis
6	Irregular sclerosis, vertical instability, old superior/inferior pubic rami	—	—	—
7	Subchondral sclerosis at pubic symphysis	Degenerative changes, sclerosis, erosions, osteophytes, cysts	—	—
8	—	Well-defined irregularities of the anterior/inferior symphysis	—	Normal
9	Obliteration of symphysis, sclerosis, vertical incongruity	Articular margins normal, subarticular cystic area	Irregularity of symphysis, no osseous edema, mild soft-tissue reaction	—
10	No changes with or without weight bearing	—	—	—

bis. In 5 patients, 1 surgeon (R.M.) carried out wedge resection using an oscillating saw to cut roughly 0.5 cm on either side of the joint. The intervening portion of bone and syn- desmosis or synchondrosis was removed. The other 2 surgeons (P.O. and P.B.) fused this joint. To fuse the symphysis pubis, a curette or drill was used to debride the fibrocarti- laginous disc and hyaline cartilage. Once adequate bleeding cancellous bone had been exposed, cancellous bone graft was harvested from the iliac crest and packed into the space. Internal fixation consisted of a 4- hole 4.5-mm reconstruction plate in 2 patients, a 6-hole 3.5-mm plate in 2 patients and a combination of a 3- hole 3.5-mm plate and a 4-hole 4.5- mm plate in an osteopenic patient.

If bleeding was brisk, a hemovac drain was left in the retropubic area.

Postoperative management

Postoperatively, antibiotics were administered prophylactically for 24 hours. Anticoagulation was not used. All those who had resection of the symphysis pubis were allowed weight bearing as tolerated. Three of the 5 patients who had a symphysiodesis were weight bearing without restriction and the other 2 were advised to ambulate with crutches for 6 weeks.

The limitation in weight bearing was based on the surgeon’s preference.

Surgical success was defined as *complete* subjective resolution of symptoms.

Results

Outcome

At an average follow up of 26 (range 0.7–70) months, all patients had some improvement. Six patients (60%) had satisfactory resolution of their symp- toms, but 4 had persistent discomfort (Table 2). In 1 of the 5 patients who had wedge resection and in 3 of the 5 who had symphysiodesis the proce- dure was considered a failure. Because of the small number of patients the prognostic importance of the history, physical examination, radiographic changes and the diagnostic injection could not be evaluated.

Complications

No postoperative infections oc- curred. One woman had posterior pelvic pain and a sensation of insta- bility at 10 months after resection of the symphysis pubis. A plain radi- ograph did not demonstrate any widening of the sacroiliac joint or de- generative changes; however, poste- rior instability has not been com-

pletely ruled out. In 1 of the 5 fusion procedures the bones failed to unite. Two years after the first fusion, a sec- ond arthrodesis was carried out. Al- though this was successful, the woman’s symptoms persisted.

Microbiologic and histologic findings

Four intraoperative specimens were taken for culture and sensitivity. All gave negative results. Specimens sent for mycobacterial cultures from 1 pa- tient were also negative. Resected portions of the symphysis pubis from 4 patients were submitted for histo- logic evaluation. There were some consistent findings. There was no evi- dence of acute inflammation and the fibrocartilaginous disk appeared nor- mal. The periosteum was normal, but the bony architecture demon- strated sclerotic changes. Various stages of degeneration of the hyaline cartilage were noted.

Discussion

Osteitis pubis is characterized by sharp or aching anterior pelvic pain centred over the symphysis pubis, in the lower abdominal muscles or in the perineum. One of the important objective findings is localized tender- ness at the symphysis pubis. Other

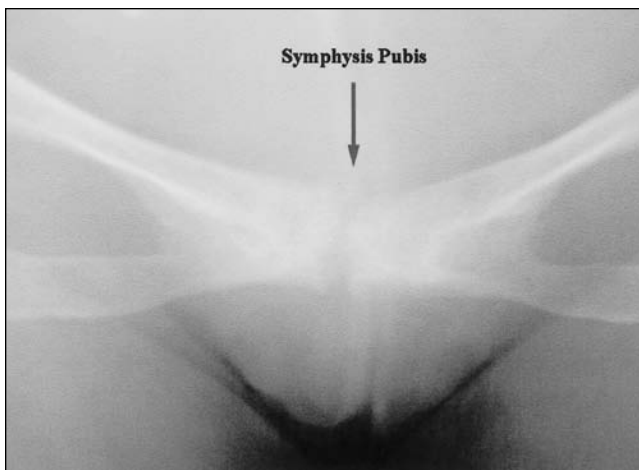


FIG. 1. Plain radiograph of the pelvis with typical changes of osteitis pubis: an irregular joint line, subchondral sclerosis and cysts.

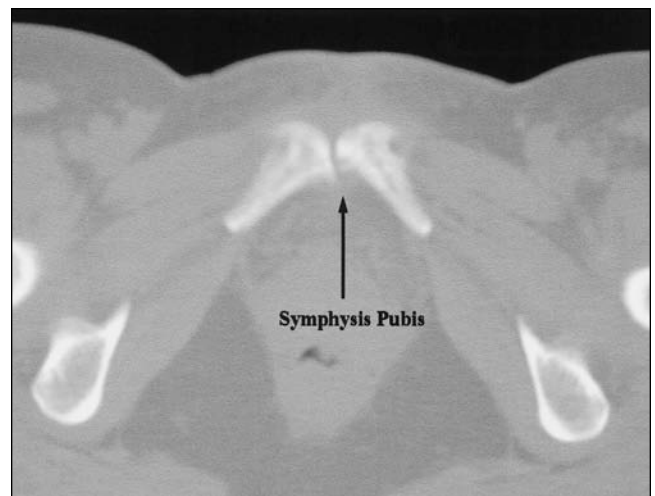


FIG. 2. CT scan of the pelvis highlights the irregular joint line of the pubis symphysis joint.

manoeuvres that stress this joint also elicit pain. A lateral compression test consists of applying force at the iliac wing when the patient is in the lateral decubitus position.¹⁴ The cross-leg test is conducted by applying a stress to the ipsilateral crossed extremity while the contralateral iliac wing is used to stabilize the pelvis.¹⁴ Other physical findings are a waddling gait and hip stiffness. Diagnostic local injection is important.¹⁵

Unfortunately, because of the paucity of cases, it is difficult to determine what are the characteristic radiographic findings of osteitis pubis. However, plain radiography and CT appear to demonstrate joint-space narrowing, subchondral irregularity, subchondral sclerosis and subchondral cysts.¹⁴ MRI illustrates variable findings of joint-space alteration, articular surface irregularity, para-articular marrow edema and

extrusions of the symphyseal disk.¹⁵

The exact cause of osteitis pubis is not known; however, it has been reported in pregnant or postpartum women, athletes and patients with rheumatologic disease.¹⁶⁻²⁶ Repetitive trauma is believed to be one cause. This may occur during pregnancy as ligamentous laxity facilitates increased motion and impaction of the articular surfaces of the symphysis. Contact sports may cause primary trauma of this site as well as secondary recurrent micromotion as a result of recurrent strains of the stabilizing ligaments. Periostitis may also be a contributing factor in athletes, especially soccer players. The adductor muscles originate at this site. Although quite rare, inflammatory osteitis pubis has been described in people with rheumatoid arthritis and ankylosing spondylitis. Some authors have hypothesized that impaired circulation is the cause and that damage of the venous plexus supplying the symphysis will lead to thrombosis and circulatory obstruction.^{7,9,27,28}

In an attempt to determine the success of surgery for osteitis pubis, we reviewed the medical literature and found reports of 73 other patients who underwent surgery (Table 3^{14,22,23,29,29-35}). It appears that osteitis pubis is not a homogeneous entity and that the necessity and success of surgery depend on the category of osteitis pubis. Having reviewed the literature, we identified 3 categories of patients with osteitis pubis: (1) elite athletes, (2) patients with infection, often after urologic or gynecologic surgery and (3) a group defined by criteria of exclusion.

Elite athletes involved in intense sports appear to respond well to surgical intervention. Williams and colleagues²³ reviewed 7 rugby players, (average age 25 yr) who had had symptoms of osteitis pubis for 27 months before surgery. At an average time of 52 months after symphysiodesis, all 7 were asymptomatic and were playing rugby again. Mullhall

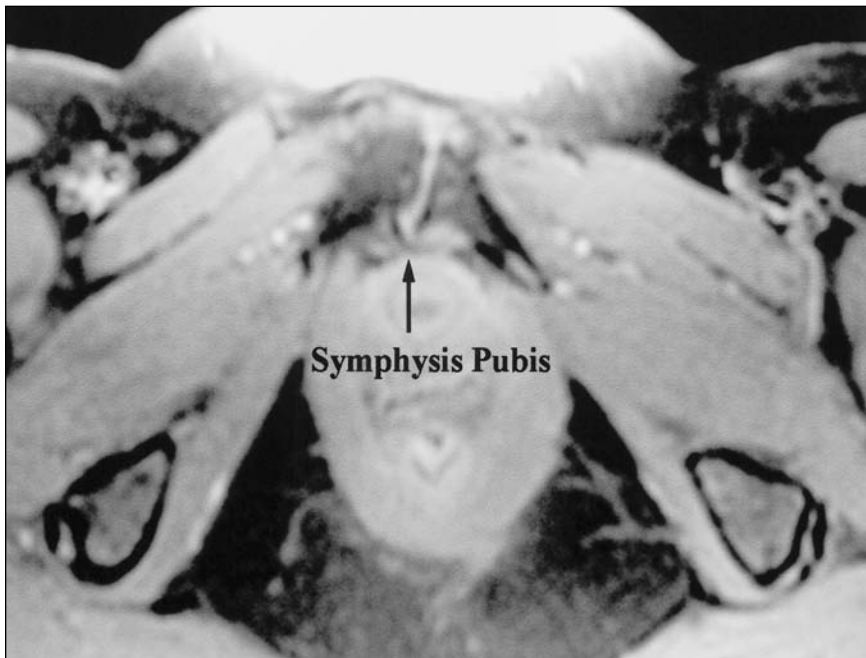


FIG. 3. T₂-weighted MR image of the pelvis demonstrates an irregular joint line, mild soft-tissue reaction anteriorly but no bone marrow edema.

Table 2

Outcome of surgery for osteitis pubis in 10 women at the University of British Columbia

No.	Age, yr	Surgery	Postoperative weight bearing	Follow-up, mo	Resolution of pain
1	49	Fusion	WBAT	39	No
2	48	Fusion	PWB	24	Yes
3	32	Fusion	WBAT	7	Yes
4	35	Fusion	PWB	13	No
5	35	Fusion	WBAT	16	No
6	41	Resection	WBAT	0.7	Yes
7	55	Resection	WBAT	10	Yes, but posterior pelvic pain developed later
8	20	Resection	WBAT	34	No
9	47	Resection	WBAT	42	Yes
10	32	Resection	WBAT	70	Yes

PWB = partial weight bearing; WBAT = weight bearing as tolerated.

and colleagues²² reported their experience with 2 soccer players who underwent curettage of the symphysis pubis. Both were asymptomatic 6 months postoperatively.

Osteitis pubis associated with infection may present as an acute illness or as chronic discomfort frequently after urologic or gynecologic surgery. Ross and Hu³⁶ reviewed all cases of infection of the symphysis pubis in the literature; 48% were related to gynecologic or urologic procedures, 19% were in athletes, 15% were related to intravenous drug use and the remaining 18% were attributed to other causes. This group has certain unique features. Whereas patients in other categories rarely (4.9%–11%) require surgery, those with infectious osteitis pubis and infection postoperatively often (55%) require surgery.^{14,27,36} Those in the infectious group respond well to surgical resection of the symphysis pubis.^{27,29–35}

All 10 patients in our series were in the third category of osteitis pubis of unknown etiology and variant presentation. All underwent surgical intervention. They were

not athletes, had no documented infection, and no symptoms beginning after a urologic or gynecologic procedure. Only 6 of these patients had complete resolution of pain after surgery. Similarly, Grace and associates¹⁴ operated on 10 females with osteitis pubis who could not be classified into categories 1 or 2. At the latest follow-up, 80% of patients had a successful outcome. This is a heterogeneous group, and because of inadequate numbers, it is difficult to identify prognostic factors that may be used to stratify these patients.

Aside from clinical presentation, another potentially important prognostic factor is the type of surgery. Four surgical procedures to treat osteitis pubis have been described: resection of the symphysis pubis by curetting the joint, by wedge resection, by complete resection of the joint or by arthrodesis of the joint.¹⁴

The pubic symphysis joint consists of a fibrocartilaginous disk in between the opposed bony surfaces of the pubis, which are covered by hyaline cartilage. This area is reinforced by ligamentous fibres superiorly and

anteriorly. Inferiorly, the symphysis is reinforced by a strong ligamentous structure known as the inferior pubic or arcuate ligament (Fig. 4). Arthrodesis of the symphysis pubis retains pelvic stability; however, it is subject to all of the restrictions and concerns that accompany surgical fusion of any joint. Specifically, there is concern of nonunion, morbidity at the bone graft harvest site and a potential need to remove the internal fixation. One woman in our series had nonunion and required a second attempt at fusion.

The other option is to resect this joint. The major concern with complete resection is the development of posterior pelvic instability and pain.³⁷ A less aggressive procedure is a wedge resection of the symphysis pubis. This takes advantage of the strong reinforcing ligamentous structures anteriorly and inferiorly. A trapezoidal wedge of bone, based cephalad and posteriorly, is removed (Fig. 5). The strong anterior and inferior arcuate ligaments are retained. Theoretically, this should maintain anterior pelvic stability and eliminate the risk of long-term posterior pelvic

Table 3

Outcome of surgery for osteitis pubis in other series

Category/series	No. of patients	Surgery	Mean follow-up	Outcome
Infection				
Cibert ²⁹	15	Excision of granulation tissue	—	11/15 success
Coventry and Mitchell ²⁷	5	1 curettage, 1 fusion, 2 partial resection, 1 complete resection	1–15 yr	5/5 success
Enzler et al ³⁰	4	Wedge resection	12–15 mo	4/4 success
Graham and Dmochowski ³¹	9	“Non-viable bone resected”	—	8/9 success
Kammerer-Doak et al ³²	15	Débridement 86%, wedge resection 14%	11.9 wk	“Partial or complete relief in all patients”
Lorenzo et al ³³	1	Local débridement	6 mo	Asymptomatic sequestrum
Petrou et al ³⁴	1	Wide resection	—	Unknown
Samellas and Finkelstein ³⁵	4	Wide resection	—	4/4 success
Elite athletes				
Mullhall et al ²²	2	Curettage	6 mo	2/2 success
Williams et al ²³	7	Arthrodesis	52 mo	7/7 success
Other				
Grace et al ¹⁴	10	Wedge resection	14 mo	10/10 success
			92 mo	7 success, 2 recurrence, 1 posterior instability
Mehin et al	10	Wedge resection	26 mo	6/10 success

instability. Moore and colleagues³⁷ reported 2 cases of posterior instability 12 and 18 years after wedge resection of the symphysis pubis. The patients presented with progressive posterior pelvic pain associated with radiographic evidence of severe sacroiliac sclerosis.

There are too few cases in the literature to draw definite conclusions

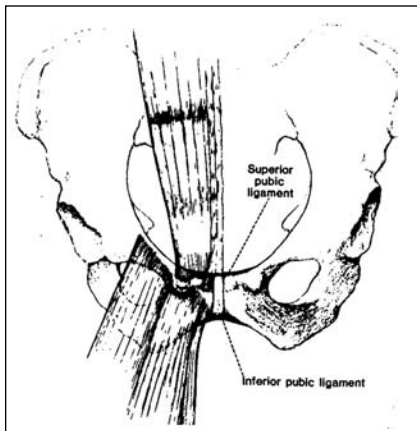


FIG. 4. The superior and inferior (arcuate) pubic ligaments must be preserved during wedge resection for osteitis pubis. Reprinted with permission from The Journal of Bone and Joint Surgery, Inc. (*J Bone Joint Surg Am* 1989;71(3):358-64).¹⁴

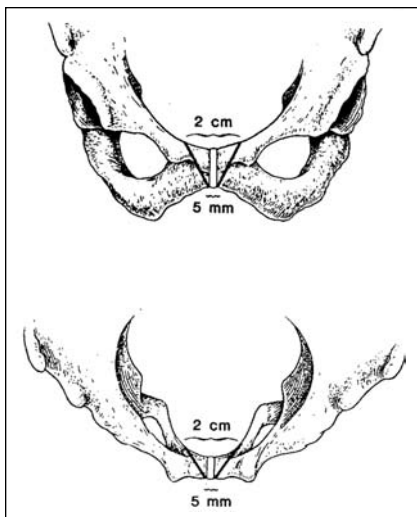


FIG. 5. The symphysis pubis is excised, in its entirety, with a trapezoidal wedge of bone, but the anterior aspect of the cortex is left intact. The base of the wedge is cephalad and posterior, and the apex is caudad and anterior. Reprinted with permission from The Journal of Bone and Joint Surgery, Inc. (*J Bone Joint Surg Am* 1989;71(3):358-64).¹⁴

about the impact of type of surgery, but certain trends are apparent. Elite athletes (category 1), appear to do well irrespective of the type of surgery. However, we recommend the least aggressive surgery, which is curettage of the joint.^{22,23} Patients with infectious osteitis pubis or infection after urologic or gynecologic surgery may do better with a wedge resection.^{27,29-35} The concern is that less aggressive surgery may result in residual infection. As for category 3 (excluded from the other 2 categories), neither the prognosis nor the ideal type of surgery is known; however, our small series demonstrates a slight advantage for wedge resection over fusion.¹⁴

Conclusions

Patients with osteitis pubis can be divided into 3 categories: elite athletes, patients with postoperative or infectious osteitis pubis and the remainder who do not fall into the first 2 categories. Elite athletes do well with surgical fusion or resection. Patients with infection are more likely to fail medical management, and up to 50% of them will require surgical intervention. The remaining patients have a 60%–80% chance of a satisfactory outcome with surgical intervention. Since wedge resection is a lesser procedure and has similar, if not better, results than fusion, we recommend wedge resection when conservative treatment fails.

Competing interests: None declared.

References

1. Beer E. Periostitis of symphysis and descending rami of the pubis following suprapubic operations. *Int J Med Surg* 1924;37:224-5.
2. Legueue MR, WL. Les cellulites perivesicales et pelviennes apres certaines cystostomies ou prostatectomies sus-pubiennes. *J Urol Med Chir* 1923;15:1-11.
3. Barnes WC, Malament M. Osteitis pubis.

Surg Gynecol Obstet 1963;117:277-84.

4. Rodriguez C, Miguel A, Lima H, et al. Osteitis pubis syndrome in the professional soccer athlete: a case report. *J Athl Train* 2001;36:437-40.
5. Daw WJ, Funke AH. Osteitis pubis treated by cortisone. *J Urol* 1953;69:686-91.
6. Holt MA, Keene JS, Graf BK, et al. Treatment of osteitis pubis in athletes. Results of corticosteroid injections. *Am J Sports Med* 1995;23:601-6.
7. Merimsky E, Canetti R, Firstater M. Osteitis pubis: treatment by heparinisation. *Br J Urol* 1981;53:154-6.
8. Mynors JM. Osteitis pubis. *J Urol* 1974;112:664-5.
9. Nissenkorn I, Servadio C, Lubin E. The treatment of osteitis pubis with heparin. *J Urol* 1981;125:528-9.
10. Nugent JJ. Osteitis pubis treated with cortisone. *J Urol* 1953;70:940-2.
11. Thornley R. Some uses of cortisone in urology, with special reference to osteitis pubis. *Br J Urol* 1955;27:1-10.
12. Lentz S. S. Osteitis pubis: a review. *Obstet Gynecol Surv* 1995;50:310-5.
13. Maksymowych WP, Aaron SL, Russell AS. Treatment of refractory symphysisitis pubis with intravenous pamidronate. *J Rheumatol* 2001;28:2754-7.
14. Grace JN, Sim FH, Shives TC, et al. Wedge resection of the symphysis pubis for the treatment of osteitis pubis. *J Bone Joint Surg Am* 1989;71:358-64.
15. O'Connell MJ, Powell T, McCaffrey NM, et al. Symphyseal cleft injection in the diagnosis and treatment of osteitis pubis in athletes. *AJR Am J Roentgenol* 2002;179:955-9.
16. Briggs RC, Kolbjornsen PH, Southall RC. Osteitis pubis, Tc-99m MDP, and professional hockey players. *Clin Nucl Med* 1992;17:861-3.
17. O'Leary JA. Osteitis pubis following vesicourethral suspension. *Obstet Gynecol* 1964;24:73-7.
18. Wiltse LL, Frantz CH. Non-suppurative osteitis pubis in the female. *J Bone Joint Surg Am* 1956;38-A:500-16.

19. Usta JA, Usta IM, Major S. Osteitis pubis: an unusual postpartum presentation. *Arch Gynecol Obstet* 2003;269:77-8.
20. Rodriguez C, Miguel A, Lima H, et al. Osteitis pubis syndrome in the professional soccer athlete: a case report. *J Athl Train* 2001;36:437-40.
21. Resnick D, Dwosh IL, Goergen TG, et al. Clinical and radiographic abnormalities in ankylosing spondylitis: a comparison of men and women. *Radiology* 1976;119:293-7.
22. Mulhall KJ, McKenna J, Walsh A, et al. Osteitis pubis in professional soccer players: a report of outcome with symphyseal curettage in cases refractory to conservative management. *Clin J Sport Med* 2002;12:179-81.
23. Williams PR, Thomas DP, Downes EM. Osteitis pubis and instability of the pubic symphysis. When nonoperative measures fail. *Am J Sports Med* 2000;28:350-5.
24. Hagen R. Pelvic girdle relaxation from an orthopaedic point of view. *Acta Orthop Scand* 1974;45:550-63.
25. Kubitz RL, Goodlin RC. Symptomatic separation of the pubic symphysis. *South Med J* 1986;79:578-80.
26. Pyle LA. Osteitis pubis in an athlete. *J Am Coll Health Assoc* 1975;23:238-9.
27. Coventry MB, Mitchell WC. Osteitis pubis: observations based on a study of 45 patients. *JAMA* 1961;178:898-905.
28. Steinbach HL, Petrakis NL, Gilfillan RS, et al. The pathogenesis of osteitis pubis. *J Urol* 1955;74:840-6.
29. Cibert J. Post-operative osteitis pubis: causes and treatment. *Br J Urol* 1952;24:213-5.
30. Enzler M, Agins HJ, Kogan M, et al. Osteomyelitis of the pubis following suspension of the neck of the bladder with use of bone anchors. A report of four cases. *J Bone Joint Surg Am* 1999;81:1736-40.
31. Graham CW, Dmochowski RR, Faerber GJ, et al. Pubic osteomyelitis following bladder neck surgery using bone anchors: a report of 9 cases. *J Urol* 2002;168:2055-7.
32. Kammerer-Doak DN, Cornella JL, Magrini JF, et al. Osteitis pubis after Marshall-Marchetti-Krantz urethropexy: a pubic osteomyelitis. *Am J Obstet Gynecol* 1998;179:586-90.
33. Lorenzo G, Meseguer MA, del Rio P, et al. Prevesical abscess secondary to pubis symphysis septic arthritis. *Pediatr Infect Dis J* 2000;19:896-8.
34. Petrou SP, Gomes CM, O'Connor MI. Osteomyelitis secondary to an osteoenteric fistula. *Urology* 1996;47:143-5.
35. Samellas W, Finkelstein P. Osteitis pubis: its surgical treatment. *J Urol* 1962;87:553-5.
36. Ross JJ, Hu LT. Septic arthritis of the pubic symphysis: review of 100 cases. *Medicine (Baltimore)* 2003;82:340-5.
37. Moore RS Jr, Stover MD, Matta JM. Late posterior instability of the pelvis after resection of the symphysis pubis for the treatment of osteitis pubis. A report of two cases. *J Bone Joint Surg Am* 1998;80:1043-8.

Change of address

We require 6 to 8 weeks' notice to ensure uninterrupted service. Please send your current mailing label, new address and the effective date of change to:

CMA Member Service Centre

1867 Alta Vista Dr.
Ottawa ON K1G 3Y6

tel 888 855-2555 or
613 731-8610 x2307
fax 613 236-8864
cmamsc@cma.ca

Changement d'adresse

Il nous faut de 6 à 8 semaines d'avis afin de vous assurer une livraison ininterrompue. Veuillez faire parvenir votre étiquette d'adresse actuelle, votre nouvelle adresse et la date de la prise d'effet du changement, à l'attention du

Centre des services aux membres de l'AMC

1867, prom. Alta Vista
Ottawa ON K1G 3Y6

tél 888 855-2555 ou
613 731-8610 x2307
fax 613 236-8864
cmamsc@cma.ca

ASSOCIATION
MÉDICALE
CANADIENNE



CANADIAN
MEDICAL
ASSOCIATION